

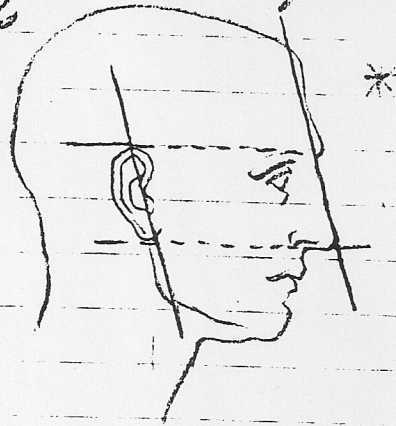


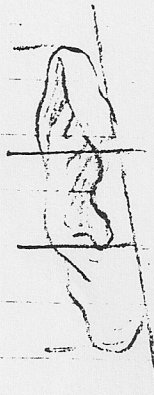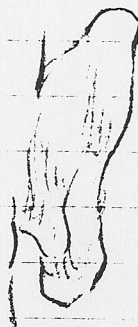

Features (cont'd)

The Ear - • General rule the direction of ear is parallel to the direction of nose.

• Also top line of ear falls horizontally, in line w/ highest pt. of eyebrows, and its lower border level w/ bottom of nose (nostrils)




Cartilage of the ear.



Features (cont'd)

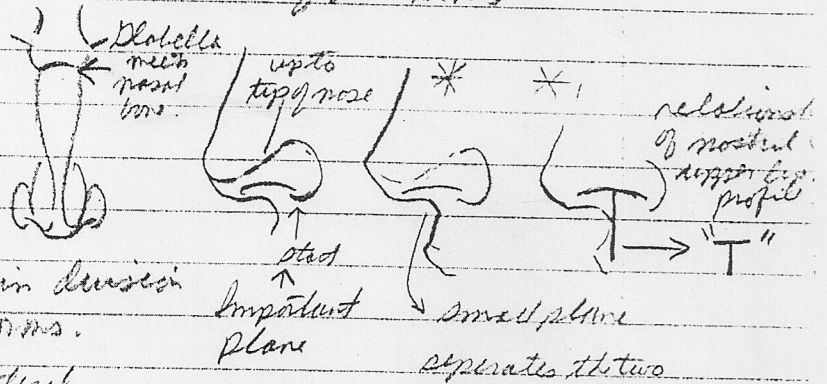
The nose -



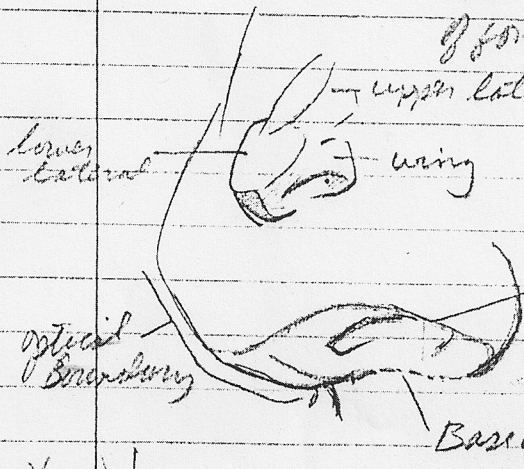
* to avoid
in making nose
appear too thin
(or thick)

Place correctly the
inner tear duct
(lacrymal fossa)
in comparison to
the nose

Pay great attention to the
correctness of these lines.



main division
of forms.


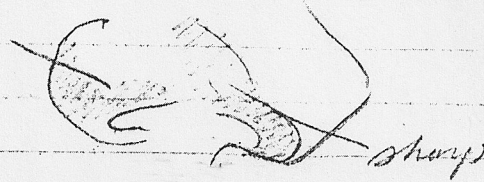
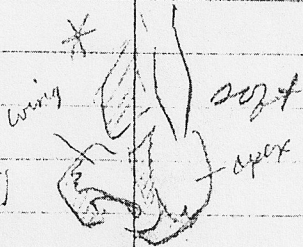


nasal bones forms
nostril origin

Dolabella
Brow
Ridge
Nose
(nasal)
bones
cartilage

lateral
surface
(side plane)
wing
nostril
apex

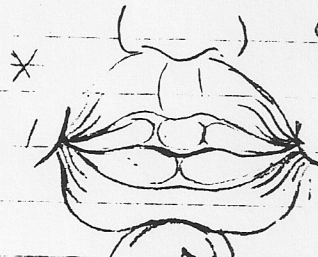
nasal spine
of maxilla



Features - Construction

The mouth - planes are produced by the orbicularis oris


Upper lip
curved plane
demonstrating
in one
turning
round itself
not extends
to corner of
mouth.





Upper lip presents
3 masses

Lower lip
2 masses

2 other large masses
under lower lip account
for orbicularis oris



Mouth wraps around
the teeth explaining



Tubercles of
upper lip

Philtrum

Carinae


wing of
upper lip

lobe of
lower lip

groove of
lower lip

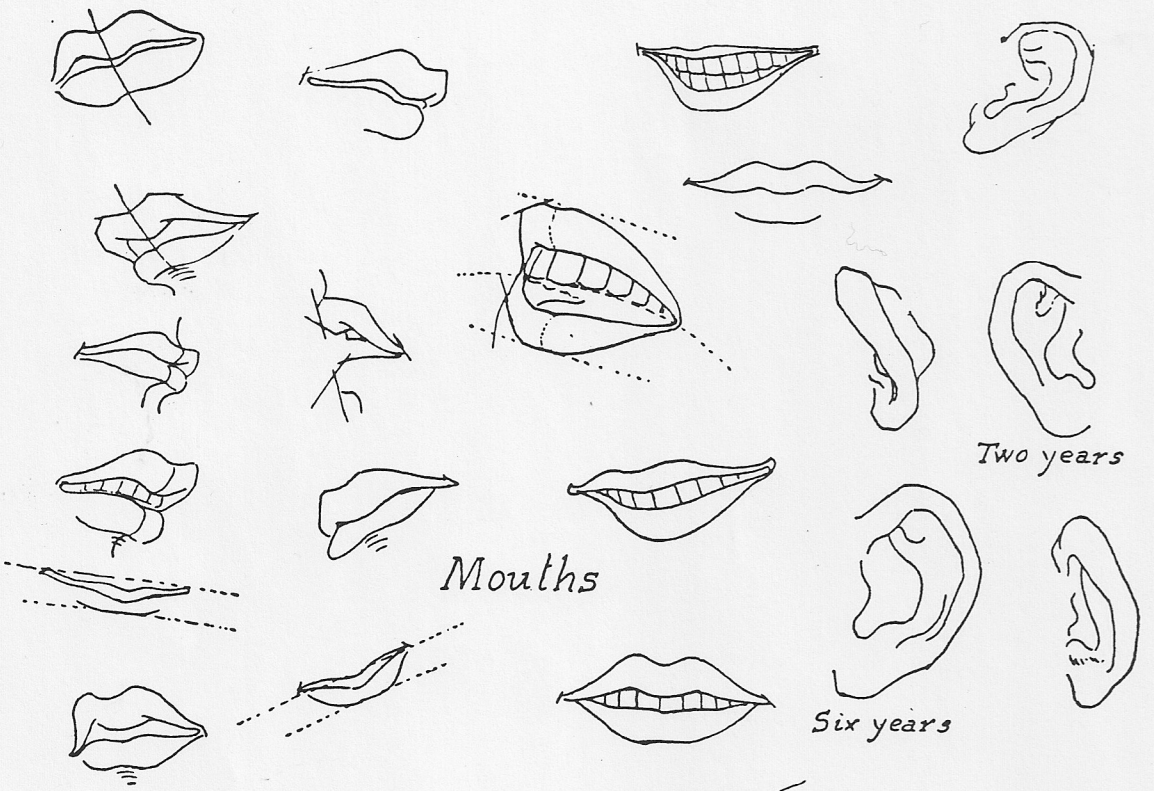

mentolabial
furrow

2 equal planes
(upper lip)



Lower lip contains
3 planes

central one is / depression in
in middle in which central
mound (bump) fits in middle

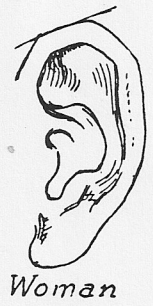

Mouths

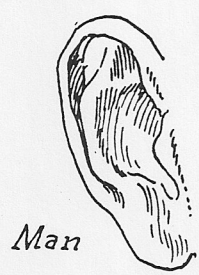Two years

Six years

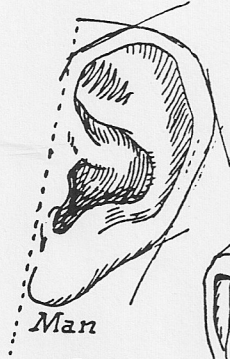Eight years



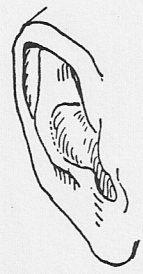Woman



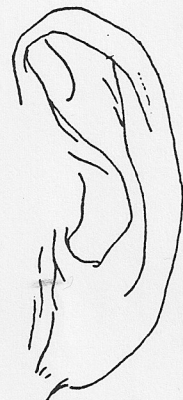
Man



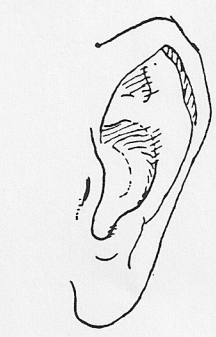
Man



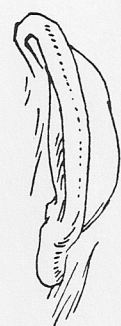Man



Old man



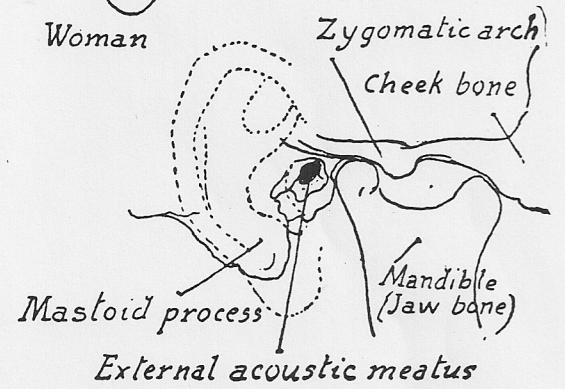
Ears



Man



Woman

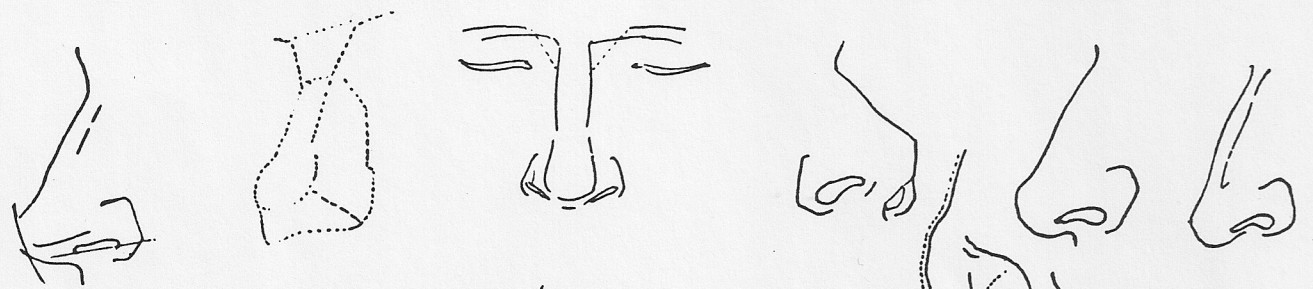
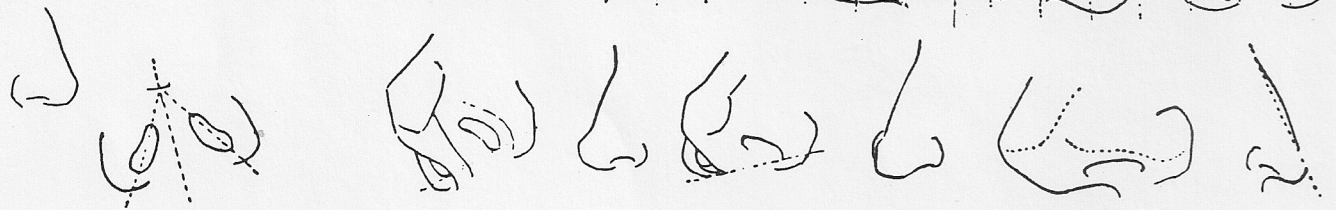

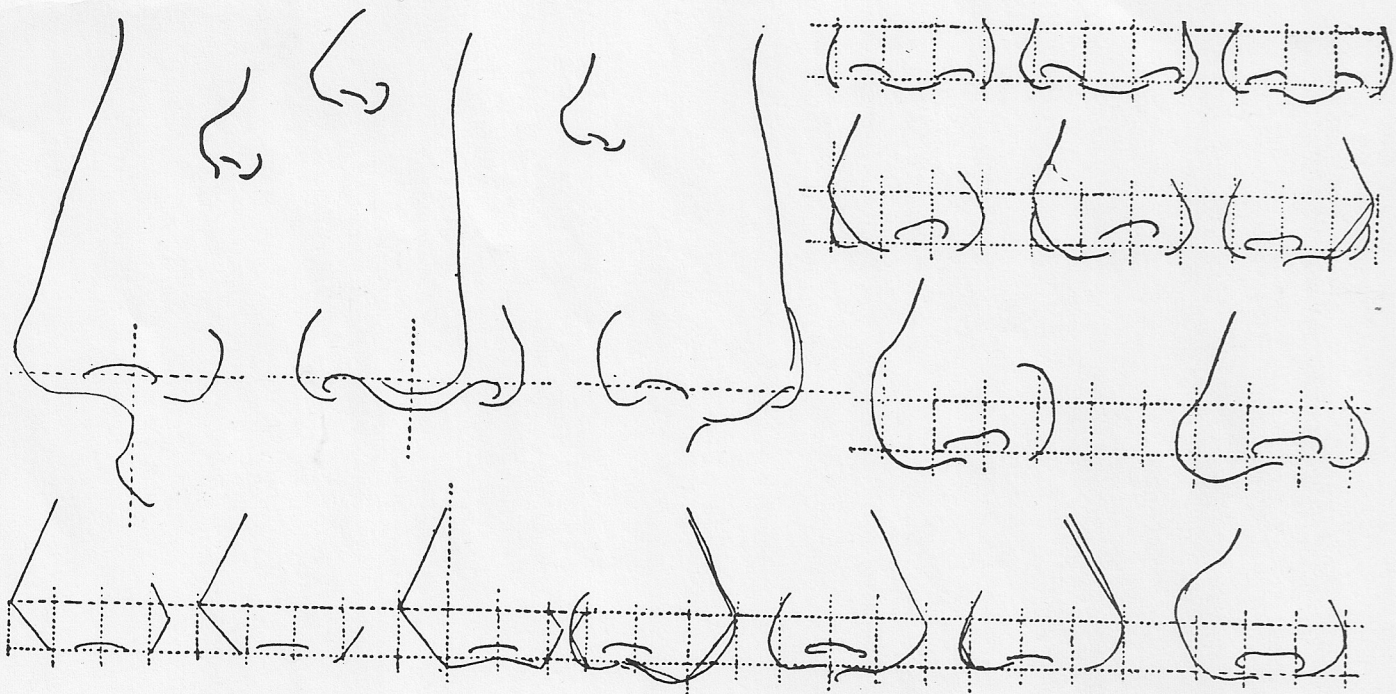


Zygomatic arch
Cheek bone

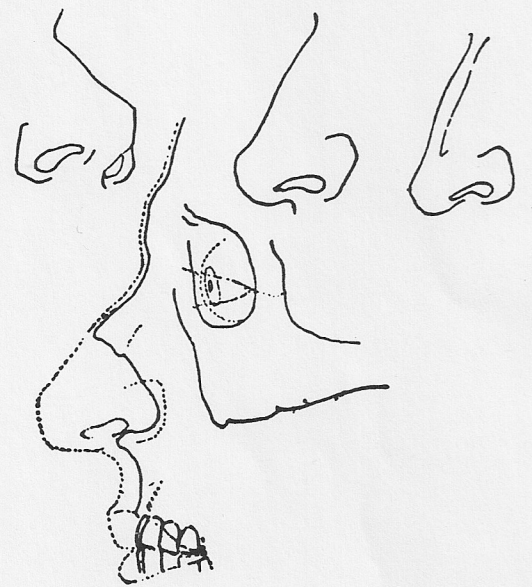
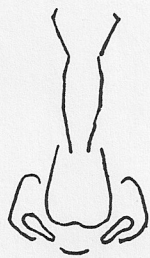
Mastoid process

Mandible
(Jaw bone)

External acoustic meatus



The Nose



Superior rectus
Fat
Rect. lateralis
Rectus inferior
Oblique inferior
External rectus

Levator palpebrarum superior
Pupil
Iris

Oblique superior
Levator palpebrarum superior
Rectus superior (cut)
Nerves
Rectus lateralis inferior
Oblique inferior

Rectus tendon
Canal
Optic nerve
Section of eye ball
Lens
Cornea
Rectus tendon

Direction of hair on an eyebrow

Nose side

EYES (PRINCIPLES & ACTION)

